

A Case Report of a Sudden Death after Recovery from a Non-Aneurysmal Subarachnoid Hemorrhage

Mahmoud Salih Abdalla Babiker

Department of Diagnostic Radiology, College of Applied Medical Science, Taibah University,
Al-Madinah Al-Munawwarah, Saudi Arabia

ABSTRACT

Background and Objective: Nonaneurysmal Subarachnoid Hemorrhage (NASAH) represents a rare type of hemorrhage that indicates blood in the space between the arachnoid and the pia mater around the brain. This condition accounts for 0.3-0.5 cases per 100,000 persons. The objective of this study is to report a case of NASAH patient. **Materials and Methods:** A seventy-three-year-old female patient was admitted to the Intensive Care Unit (ICU)-due to a sudden severe headache and lower limb weakness, followed by unconsciousness with no history of diagnosed clinical condition. **Results:** The clinical examination indicated severe uncontrolled hypertension and the conventional Computerized Tomography (C.T.) brain images showed diffuse Subarachnoid Hemorrhage (SAH). The onset was treated by empiric therapy, monitoring the invasive blood pressure (B.P. and using nimodipine). The patient became conscious and well-recovered after 2 weeks of the ICU admission and another non-contrast brain C.T. after the recovery showed unremarkable findings. The patient was discharged from the hospital and directed to use an antihypertensive drug and come back after two weeks for follow-up. Unfortunately, four days later after the discharge, the patient suddenly died. **Conclusion:** Computerized tomography is a valuable method for diagnosing NASAH. Nimodipine was the optimum treatment for this patient besides the empiric therapy. Careful diagnosis and adequate treatment of NASAH are advisable to avoid severe complications.

KEYWORDS

Nonaneurysmal, subarachnoid, hemorrhage, aneurysmal, bleeding

Copyright © 2024 Mahmoud Salih Abdalla Babiker. This is an open-access article distributed under the Creative Commons Attribution License, which permits unrestricted use, distribution and reproduction in any medium, provided the original work is properly cited.

INTRODUCTION

A Subarachnoid Hemorrhage (SAH) is an accumulation of blood in the space between the arachnoid and the pia mater around the brain. Claassen and Park¹ indicated that SAH is the third most common stroke subtype. Still, its incidence has decreased over the past decades due to lifestyle changes such as smoking cessation and management of hypertension. The SAH can be due to trauma or occurs spontaneously, about 85% of cases of spontaneous SAH are caused by ruptured intracranial aneurysms (aneurysmal SAH). The remainder (15%) includes non-aneurysmal peri mesencephalic, Macdonald² and Wolfert *et al.*³ have proposed that the Nonaneurysmal Subarachnoid Hemorrhage (NASAH) is a rare



type of SAH. Roman-Filip *et al.*⁴ indicated that the NASAH incidence ranges between 0.3 and 0.5 cases per 100,000 persons. Maher *et al.*⁵ suggested that spontaneous Subarachnoid Hemorrhage (SAH) was associated with a more significant proportion of morbidity and mortality. Some authors have shown that this condition can be diagnosed by Computed Tomography (C.T.) as a first diagnostic test. However, when unremarkable, the next step should be a lumbar puncture¹.

Case report: In June, 2020 a seventy-three-year-old female patient was admitted to the Intensive Care Unit (ICU)-at Al Bangadded Hospital-Khartoum-(The case report ended in July, 2024). The patient's symptoms began with a sudden severe headache and lower limb weakness, then became unconscious. In the ICU unit, severe uncontrolled hypertension was detected clinically. She has no previous history of diagnosed clinical conditions. The neurologist requested a C.T. brain, the conventional C.T. brain images showed a diffuse extension of SAH with blood from the basilar cisterns, covering the Sylvian fissures and extending to the interhemispheric fissure (Fig. 1). The unconsciousness condition was managed initially through starting empiric therapy, like oxygenation and intravenous (IV) fluids for circulation control, then invasive blood pressure (B.P.) monitoring and using nimodipine for cerebral vasospasm (CV) prevention. After two weeks of the ICU admission, the patient became conscious. Another non-contrast brain C.T. after the recovery showed unremarkable findings and no evidence of hemorrhage (Fig. 2). After a good recovery, the patient was discharged from the hospital with no complaints of symptoms other than fatigue. She was directed to use an antihypertensive drug regularly and come back after two weeks for follow-up. Unfortunately, four days later after the discharge, the patient suddenly died without any complaints.

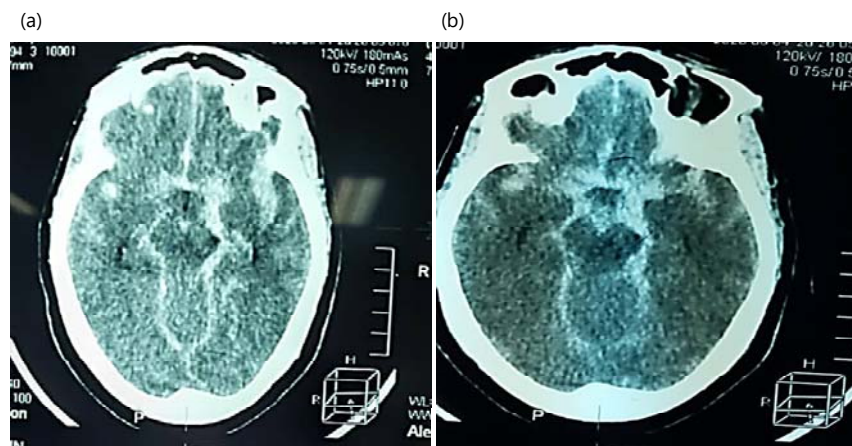


Fig. 1: Conventional C.T. brain images showed a diffuse extension of SAH
Presence of blood from the basilar cisterns, covering the Sylvian fissures and extending to the interhemispheric fissures

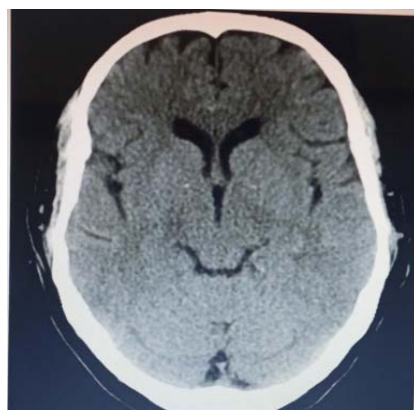


Fig. 2: Non-contrast C.T. image demonstrating the improvement of the patient after the treatment with no appearance of the SAH

DISCUSSION

The clinical examination for the current case indicated severe uncontrolled hypertension and the C.T. brain images showed a diffuse extension of SAH, the blood extended from the basilar cisterns, covering the Sylvian fissures and extending to the interhemispheric fissures. Standard methods were applied to diagnose, treat and monitor the onset. A conventional C.T. was used to diagnose the condition. The patient became conscious and well-recovered through empiric therapy, monitoring the B.P. and using nimodipine. The patient was discharged after the recovery and the unremarkable second brain C.T. findings.

The intracranial subarachnoid spaces (SAS) are fluid-filled intercommunicating spaces containing Cerebrospinal Fluid (CSF) circulating within the basal cisterns. They are located between the meningeal layers of the arachnoid and pia mater⁶. The SAH is life-threatening and results from the presence of blood in the (SAS)⁷. The SAH can be due to trauma or occurs spontaneously, about 85% of cases of spontaneous SAH are caused by ruptured intracranial aneurysms (aneurysmal SAH). The remainder (15%) includes NASAH².

Some authors have indicated that the (NASAH) is a rare type of (SAH) and potentially life-threatening lesion and has an annual overall incidence range from 0.3-0.5 cases per 100,000 persons^{3,8}. Hypertension, smoking, cocaine and alcohol usage are considered common risk factors for NASAH⁹. Dabilgou *et al.*¹⁰ suggested that the leading cause of spontaneous subarachnoid hemorrhage is hypertension, which occurs in 77.9% of (NASAH) patients. The patients suffering from non-aneurysmal SAH have a better prognosis compared to aneurysm-related SAH¹¹.

Regarding the diagnosis of NASAH, Trinh and Massoud⁶ reported the C.T., diagnoses this condition as a first diagnostic test, if the C.T. is unremarkable, the next step should be a lumbar puncture. Hou and Yu¹² proposed that NASAH is considered when SAH is centered in focal peri-mesencephalic cisterns. When the diagnosis is unremarkable by lumbar puncture, the other options should be Magnetic Resonance Imaging (MRI) and magnetic resonance angiography (MRA) or C.T., angiography (CTA)⁵. Haugh *et al.*¹³ concluded that when blood is in the Sylvian fissure, the outcomes and rates of complication from NASAH are worse.

Regarding the treatment of NASAH, Osman and Rames¹⁴ have shown that the etiology remains unknown in most cases and there are no specific treatments for NASAH. The current case study proved that NASAH needs specific treatments. Our patient's condition was treated initially by empiric therapy to manage the unconsciousness condition, some procedures were applied, like oxygenation and IV fluids for circulation control, then invasive blood pressure (B.P.) monitoring and using nimodipine. Wolfert *et al.*³ surveyed to evaluate the clinical management of NASAH among 135 neurosurgical departments, they have concluded that invasive B.P. monitoring is usually performed more often in severe NASAH. This conclusion supported the current case study report. Liu *et al.*¹⁵ provided a semi-lateral conclusion, they reported that nimodipine effectively treats SAH with a lower incidence of adverse reactions.

Baggott and Aagaard-Kienitz¹⁶ have reported that nimodipine significantly affects cerebral circulation more than peripheral circulation compared to other calcium channel-blocking agents. They added that nimodipine inhibits the calcium influx in smooth muscle cells and prevents calcium-dependent smooth muscle contraction and subsequent vasoconstriction.

In a cohort study of 67 NASAH patients, Lago *et al.*¹⁷ suggested that the mortality rate was 6.6% during the follow-up period. Tarkiainen *et al.*¹⁸ have shown that the severity of the bleeding in NASAH patients has similar risk factors for poor outcomes as patients with aneurysmal SAH. This conclusion may explain the sudden death of our patient in this current case study.

CONCLUSION

Computed tomography is a valuable method for diagnosing NASAH. Indeed, confirming the diagnosis by angiography is advisable to exclude an intracranial aneurysm or underlying vascular malformation. Nimodipine was the optimum treatment for this patient besides the empiric therapy. The NASAH should be carefully diagnosed and adequately treated through multiple diagnostic methods. Moreover, NASAH may be associated with sudden death even after the recovery. Monitoring and controlling hypertension is necessary and may have a role in avoiding NASAH attacks or decreasing the mortality rate.

SIGNIFICANCE STATEMENT

The objective of this study is to report a case of Nonaneurysmal Subarachnoid Hemorrhage (NASAH) patient. The NASAH may be associated with high mortality and sudden death even after the recovery. The current case report indicated that NASAH should be carefully diagnosed through multiple diagnostic methods and adequately treated. Conventional C.T., angiography and Magnetic Resonance Imaging (MRA) angiography are essential in diagnosing NASAH and excluding the ASAH. As this current case was about a hypertensive patient, its outcomes indicated that monitoring and controlling hypertension is necessary and may have a vital role in avoiding NASAH attacks. The author recommends conducting a prospective study using a significant sample size of a cohort of NASAH patients to achieve more accurate results and reach sound conclusions regarding this condition.

ACKNOWLEDGMENT

The author is grateful to the intensive care unit staff at Al Bangaddad Hospital for their cooperation.

REFERENCES

1. Claassen, J. and S. Park, 2022. Spontaneous subarachnoid haemorrhage. *Lancet*, 400: 846-862.
2. Macdonald, R.L., 2018. Subarachnoid Hemorrhage. In: *Handbook of Neuroemergency Clinical Trials*, Skolnick, B.E. and W.M. Alves (Eds.), Academic Press, Cambridge, Massachusetts, ISBN: 978-0-12-804064-5, pp: 23-45.
3. Wolfert, C., C.J. Maurer, B. Sommer, K. Steininger and S. Motov *et al.*, 2023. Management of perimesencephalic nonaneurysmal subarachnoid hemorrhage: A national survey. *Sci. Rep.*, Vol. 13. 10.1038/s41598-023-39195-2.
4. Roman-Filip, I., V. Morosanu, Z. Bajko, C. Roman-Filip and R.I. Balasa, 2023. Non-aneurysmal perimesencephalic subarachnoid hemorrhage: A literature review. *Diagnostics*, Vol. 13. 10.3390/diagnostics13061195.
5. Maher, M., T.A. Schweizer and R.L. Macdonald, 2020. Treatment of spontaneous subarachnoid hemorrhage: Guidelines and gaps. *Stroke*, 51: 1326-1332.
6. Trinh, A. and T.F. Massoud, 2023. Imaging of the Subarachnoid Space and Cerebrospinal Fluid. In: *Cerebrospinal Fluid and Subarachnoid Space*, Tubbs, R.S., J. Iwanaga, E.B. Rizk, A.V. D'Antoni and A.S. Dumont (Eds.), Academic Press, United States, ISBN: 978-0-12-819509-3, pp: 273-296.
7. Ziu, E., M.Z.K. Suheb and F.B. Mesfin, 2023. Subarachnoid Hemorrhage. *StatPearls*, Treasure Island.
8. Flaherty, M.L., M. Haverbusch, B. Kissela, D. Kleindorfer and A. Schneider *et al.*, 2005. Perimesencephalic subarachnoid hemorrhage: Incidence, risk factors, and outcome. *J. Stroke Cerebrovascular Dis.*, 14: 267-271.
9. Thilak, S., P. Brown, T. Whitehouse, N. Gautam, E. Lawrence, Z. Ahmed and T. Veenith, 2024. Diagnosis and management of subarachnoid haemorrhage. *Nat. Commun.*, Vol. 15. 10.1038/s41467-024-46015-2.
10. Dabilgou, A.A., A. Drave, J.M.A. Kyelem, L. Naon, C. Napon and J. Kabore, 2019. Spontaneous subarachnoid haemorrhage in neurological setting in Burkina Faso: Clinical profile, causes, and mortality risk factors. *Neurol. Res. Int.*, Vol. 2019. 10.1155/2019/8492376.

11. Konczalla, J., J. Platz, P. Schuss, H. Vatter, V. Seifert and E. Güresir, 2014. Non-aneurysmal non-traumatic subarachnoid hemorrhage: Patient characteristics, clinical outcome and prognostic factors based on a single-center experience in 125 patients. *BMC Neurol.*, Vol. 14. 10.1186/1471-2377-14-140.
12. Hou, K. and J. Yu, 2022. Current status of perimesencephalic non-aneurysmal subarachnoid hemorrhage. *Front. Neurol.*, Vol. 13. 10.3389/fneur.2022.960702.
13. Haugh, J.P., Z. Turkalp, H. Sivam, S. Gatt and C. Kaliaperumal, 2022. Treatment and outcomes of non-aneurysmal perimesencephalic subarachnoid haemorrhage: A 5 year retrospective study in a tertiary care centre. *Clin. Neurol. Neurosurg.*, Vol. 222. 10.1016/j.clineuro.2022.107448.
14. Osman, N. and N. Ramesh, 2018. Perimesencephalic non-aneurysmal subarachnoid haemorrhage. *BMJ Case Rep.*, Vol. 2018. 10.1136/bcr-2018-224933.
15. Liu, J., C. Sun, Y. Wang, G. Nie and Q. Dong *et al.*, 2022. Efficacy of nimodipine in the treatment of subarachnoid hemorrhage: A meta-analysis. *Arquivos Neuro-Psiquiatria*, 80: 663-670.
16. Baggott, C.D. and B. Aagaard-Kienitz, 2014. Cerebral vasospasm. *Neurosurg. Clin. North Am.*, 25: 497-528.
17. Lago, A., R. López-Cuevas, J.I. Tembl, G. Fortea, D. Górriz, F. Aparici and V. Parkhutik, 2016. Short- and long-term outcomes in non-aneurysmal non-perimesencephalic subarachnoid hemorrhage. *Neurol. Res.*, 38: 692-697.
18. Tarkiainen, J., V. Hovi, L. Pyysalo, A. Ronkainen and J. Frösen, 2023. The clinical course and outcomes of non-aneurysmal subarachnoid hemorrhages in a single-center retrospective study. *Acta Neurochirurgica*, 165: 2843-2853.