

Evaluation of the Ameliorative Potential of Some Fertility Herbal Supplements on Male Fertility Hormones and Semen Parameters of Lead Acetate Induced Toxicity in Albino Rats

¹Arit Okechukwu Nwogu, ¹Oni Emmanuel Sunday, ²Tamuno-Boma Odinga, ¹Chukwu Priya Homa, ¹Jonathan Nyebuchi, ¹Anyalebechi Eberechi Okwuchi and ²Udomine Brantley Akuru
¹Department of Medical Laboratory Science, Faculty of Science, Rivers State University, Port Harcourt, Nigeria
²Department of Biochemistry, Faculty of Science, Rivers State University, Port Harcourt, Nigeria

ABSTRACT

Background and Objective: Herbal substances are used by many societies to treat health challenges and curb fertility issues. This study evaluated the efficacy of three different male fertility herbal supplements (Libron herbal, Mascum herbal pride and Energy 3000) in ameliorating lead acetate-induced infertility in adult male albino rats. **Materials and Methods:** Twenty male rats were grouped A (negative control), B (positive control), C (Libron-treated), D (Mascum-treated) and E (Energy 3000-treated). Lead acetate (60 mg/kg) was used to induce male infertility in all groups except the negative control. The rats were treated with the herbal supplements for 28 days after which they were sacrificed. Blood samples were collected for analysis using standard laboratory methods while the testes were harvested for histological examination. Semen analysis was microscopically evaluated. Data obtained were statistically analyzed using SPSS version 25. **Results:** The mean testosterone values for Mascum treated group (3.65 ± 0.79 ng/mL) and Energy 3000 treated group (3.56 ± 0.56 ng/mL) were significantly ($p < 0.05$) higher than the positive control group (1.58 ± 0.22 ng/mL) but significantly ($p < 0.05$) lower than the negative control ($p < 0.001$). The mean LH levels of Libron herbal (37.10 ± 2.93 mIU/mL) and Mascum herbal (32.53 ± 2.92 mIU/mL) were not significantly higher than that of the positive control whereas, FSH and Inhibin B levels of the treated groups were significantly ($p < 0.05$) higher than that of the positive control apart from mean values of FSH in Energy 3000 treated group. **Conclusion:** Mascum herbal and Energy 3000 used in this study showed some ameliorative potential in the management of male reproductive challenges. It is thus recommended that studies be done to establish the efficacy of different herbal supplements out there in the open market.

KEYWORDS

Male infertility, semen analysis, follicle stimulating hormone, testosterone, leutizing hormone, inhibin, herbal supplements, ameliorative potential

Copyright © 2024 Nwogu et al. This is an open-access article distributed under the Creative Commons Attribution License, which permits unrestricted use, distribution and reproduction in any medium, provided the original work is properly cited.



INTRODUCTION

Infertility refers to the biological inability of an individual to achieve pregnancy following at least 12 months of unprotected sexual intercourse¹. Infertility in males appears to contribute approximately 20-50% of the population and this is associated with abnormal results of semen analysis². Infertility in men occurs when a man fails to achieve pregnancy in a fertile female whose fertility status is proven satisfactory³.

Globally, herbal supplements are an integral part of traditional medicine developed by a group of people. It is unique, adapted and defined by their culture and beliefs to satisfy the health needs of their communities⁴. These supplements are consumed alongside other diets to meet daily body needs for optimal function or to aid in the treatment of a particular ailment⁵.

Herbal substances are used by many societies to maintain health and treat health challenges. Plants generally contain active ingredients that are being used in producing conventional drugs⁶. For example, salicylic acid, a precursor of aspirin was originally derived from white willow bark and meadow sweet plant (*Filipendula ulmaria*). As such its usage and sale are approved since it seems to be derived basically from a natural source⁷.

These herbal supplements are made up of several plants that contain different phytochemicals that has been shown to be of enormous benefits in biological system. Mascum herbal, Libron herbal and Energy 3000 have been shown to contain various phytochemicals as seen in a study by Nwogu *et al.*⁸. Studies show that these phytochemicals may possess good antioxidants, antibacterial, anticarcinogenic, antimutagenic, antiviral and anti-inflammatory activities because they act as free radical scavengers as they are potentially reducing agents protecting organs from oxidative damage due to the presence of hydroxyl groups^{9,10}.

Research shows that 80% of people in developing countries rely on herbal supplements for the treatment of different ailments which is believed to be safe¹¹. Herbal supplements have been reported to be used by the populace. Its safety has remained untested, hence, lacks suitable quality controls. Due to this, there is a need to assess its suitability and obtain appropriate information on its usage¹².

Recently, there has been an upsurge in the usage of these herbal supplements and this has prompted WHO to integrate herbal supplements into the national healthcare system and to set out a policy to regulate their usage in some countries¹³. Therefore, this study is aimed at evaluating the ameliorative potential of some herbal supplements namely Libron herbal, Mascum herbal pride and Energy 3000 in lead acetate induced alteration in male fertility hormones.

MATERIALS AND METHODS

Study area: The study was carried out in the Animal House of the Department of Pharmacology, University of Port Harcourt, Choba, Nigeria from July, 2022 to September, 2022.

Experimental animals: Twenty-eight male albino rats, weighing 150-250 g were purchased from the Pharmacology Department of the University of Port Harcourt, Rivers State. The rats were allowed access to standard feed (finisher) manufactured by Top Feeds Nig. Ltd and water *ad libitum*. They were housed in compartmentalized cages and allowed to acclimatize for two weeks.

Experimental drugs: Lead acetate, a product of Kermel Pharmaceuticals, China, was purchased from a chemical shop in Port Harcourt, Rivers State. The three herbal supplements used in this study, (Libron Herbal Capsule, Mascum herbal pride and Energy 3000), were purchased from commercial herbal stores in Port Harcourt, Nigeria and they are all made up of various medicinal plants.

Determination of LD₅₀ of lead acetate¹⁴: This was done using the two stages of Lorke's method. Upon calculation, 49 mg/kg was obtained.

Pilot study: Eight male Wistar albino rats weighing 150-250 g were purchased from the animal house in the Pharmacology Department, University of Port Harcourt. They were grouped into four groups of two rats each. Lead acetate was administered at the following doses: 9 mg/kg was given to Group A, 18 mg/kg to Group B, 30 mg/kg to Group C and 60 mg/kg to Group D for three weeks to determine the concentration that would bring about the lowest sperm concentration. Sixty mg/kg gave the lowest sperm concentration of semen parameters.

Induction of infertility using 60 mg/kg lead acetate: All the rats in Groups B, C, D and E were given 60 mg/kg of lead acetate for 3 weeks to induce infertility based on the pilot study result obtained. This was similar to the method of Ibrahim *et al.*¹⁴ and Owumi *et al.*¹⁵.

Determination of therapeutic doses of herbal drugs: The therapeutic doses of the herbal drugs were determined based on the method of Paget and Barnes¹⁶. The doses on a daily basis were determined using the OECD's guidelines as reputed by Odinga *et al.*¹⁷.

Treatment of the rats: After induction of infertility, the albino rats in Group C were treated with 20.3 mg/kg of Libron Herbal, Group D with 17.6 mg/kg of Mascum Herbal Pride and Group E with 0.81 mg/kg Energy 3000 herbal supplements. The supplements were given orally by gastric lavage to the albino rats daily for 28 days.

Experimental design: The experimental animals (20) were grouped into five Groups containing four rats each. The grouping was thus:

- **Group A:** Negative control; Normal diet+water.
- **Group B:** Positive control; 60 mg/kg lead acetate+normal diet+water
- **Group C:** 60 mg/kg lead acetate+20.3 mg/kg Libron herbal supplement
- **Group D:** 60 mg/kg lead acetate+17.6 mg/kg Mascum herbal
- **Group E:** 60 mg/kg lead acetate+0.81 mg/kg Energy 3000 herbal

Biochemical analysis: At the end of the 28 days, the rats were anaesthetized and sacrificed on the 29th day. Blood samples were collected via cardiac puncture into plain containers and allowed to clot for the collection of serum for biochemical analysis. Testosterone, FSH, LH and inhibin B were estimated quantitatively by the sandwich Enzyme-Linked Immunosorbent Assay (ELISA) technique using Auto Elisa P microplate reader (Labtech). Semen analysis was carried out microscopically and the testes were harvested and stored in 10% formalin for histological analysis.

Statistical analysis: All data generated from this study were analyzed using Statistical Package for Social Sciences (SPSS) version 23. Results were expressed as Mean±Standard Deviation. Comparison of means was made for the various parameters using the One-way Analysis of Variance (ANOVA). The *post hoc* was done with Tukey's Multiple Comparison Analysis Test. Results were considered statistically significant at 95% confidence interval ($p \leq 0.05$).

RESULTS

Table 1 describes the values of the reproductive hormones. The results indicate that herbal supplements had ameliorative effects on the lead acetate-induced toxicity of the reproductive system of the rats apart from Libron herbal.

Table 2 describes the values of the semen parameters. The results indicate significant improvements in the semen parameters in the treated groups when compared to the positive groups apart from group treated with Libron herbal.

Histological examination: Figure 1a indicates the presence of vacuolated seminiferous tubules containing spermatogonia (SPG) and few spermatocytes (SPC) with surrounding basement membrane (BM) and Interstitial space (ISS) containing Leydig cells. Figure 1b shows normal seminiferous tubules with a non-distorted basement membrane (BM), containing normal spermatogonia (SPG), spermatocyte (SPC), spermatozoa (SPZ) and interstitial space (ISS) containing Leydig cells.

Table 1: Comparison of hormone levels

	Testo (ng/mL)	LH (mIU/mL)	FSH (mIU/mL)	INHIBIN-B (pg/mL)
PC	1.58±0.22 ^a	30.83±0.54 ^a	2.63±0.57 ^a	99.61±6.25 ^a
NC	5.03±0.22 ^b	44.43±1.84 ^b	3.33±0.22 ^b	121.40±14.25 ^b
LT	0.98±0.63 ^a	37.10±2.93 ^a	3.25±0.29 ^c	138.13±18.67 ^c
MT	3.65±0.79 ^c	32.53±2.92 ^a	3.73±0.59 ^b	152.67±1.35 ^d
ET	3.56±0.56 ^c	50.98±6.83 ^b	2.43±0.25 ^a	153.45±18.70 ^d
p-value	<0.001	<0.001	0.003	<0.001
F-value	44.161	188.546	6.530	26.501
Remark	S	S	S	S

PC: Positive control, NC: Negative control, LT: Libron therapeutic, MT: Mascum therapeutic, ET: Energy 3000 therapeutic, Testo: Testosterone, LH: Luteinizing hormone and FSH: Follicle stimulating hormone, *post hoc*: Values with different superscripts differ significantly at p<0.05, S: Significant and NS: Non-significant

Table 2: Mean value of semen parameters of rats treated for 4 weeks with the herbal supplements

	Viability (%)	Active motility (%)	Sluggish (%)	Dead (%)	Count (×10 ⁶ /mL)
PC	55.78±4.36 ^a	48.50±5.07 ^a	7.50±8.43 ^a	22.00±5.42 ^a	102.30±17.08 ^a
NC	81.25±4.79 ^b	83.75±4.79 ^b	7.50±2.89 ^b	8.75±2.50 ^b	550.00±57.74 ^b
LT	60.00±7.07 ^a	61.75±5.38 ^c	19.50±4.95 ^c	14.25±6.29 ^c	260.10±29.44 ^c
MT	78.75±4.79 ^d	71.75±2.36 ^d	10.10±1.00 ^d	18.26±2.36 ^d	425.00±20.82 ^d
ET	73.75±4.79 ^e	70.50±4.20 ^d	13.25±3.95 ^d	16.25±4.70 ^c	440.00±31.62 ^d
F-value	12.381	8.113	5.811	10.101	14.921
p-value	<0.001	<0.001	<0.001	<0.033	<0.001

PC: Positive control, NC: Negative control, LT: Libron therapeutic, MT: Mascum therapeutic, ET: Energy 3000 therapeutic, *post hoc*: Values with different superscripts differ significantly at p<0.05, S: Significant and NS: Non-significant

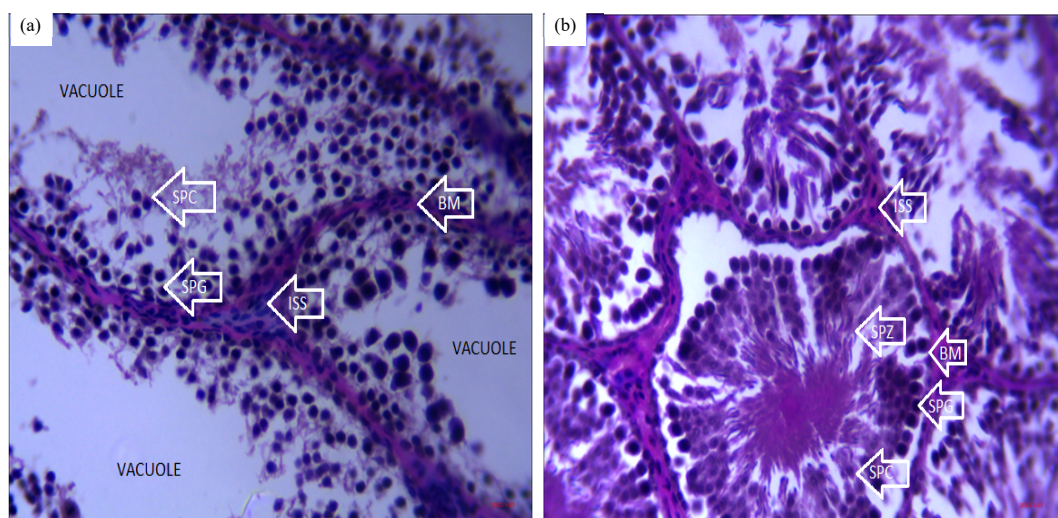


Fig. 1(a-b): Histology of H&E staining of Positive Control and the Negative Control Groups, (a) Photomicrograph of Positive Control week 4 (H&E Stain ×400) indicating the presence of vacuolated seminiferous tubules and (b) Photomicrograph of Negative Control week 4 (H&E Stain ×400), showing normal testis

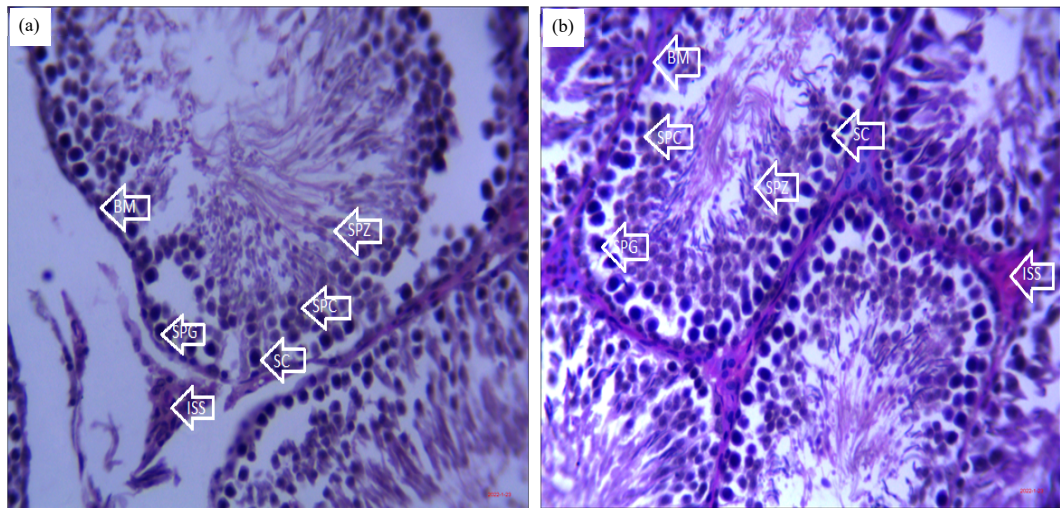


Fig. 2(a-b): Histology of H&E staining of Libron and Mascum treated groups, (a) Pictomicrograph of Libron therapeutic effect on testis at week 4 (H&E Stain ×400) showing slightly distorted testis and (b) Pictomicrograph of Mascum therapeutic effect on testis at week 4 (H&E Stain ×400) showing histologically normal testis

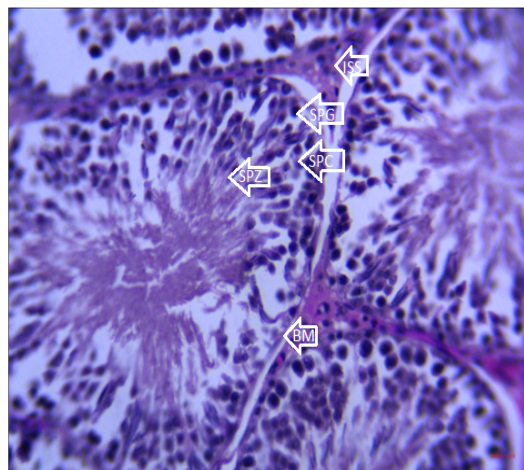


Fig. 3: Representation of the histology of H&E staining of Energy 3000 treated group. Pictomicrograph of Energy 3000 Therapeutic effect on testis at week 4 (H&E Stain ×400)

Histologically normal testis:

- Normal shaped seminiferous tubules with basement (BM), containing spermatogonia (SPG), spermatocyte (SPC) and spermatozoa (SPZ)
- Interstitial space (ISS) containing Leydig cells (Fig. 3)

Figure 2a shows interstitial space (ISS) containing Leydig cells and normal shaped seminiferous tubules lined with basement membrane (BM), containing spermatogonia (SPG), reduced spermatocyte (SPC) and spermatozoa (SPZ). Figure 2b shows histologically normal testis: (a) Normal shaped tubules with intact basement membrane (BM) containing spermatogonia (SPG), spermatocyte (SPC) and spermatozoa (SPZ) and (b) Interstitial space (ISS) containing Leydig cells.

DISCUSSION

This study evaluated the ameliorative potential of some fertility herbal supplements on male fertility hormones and sperm viability of lead acetate treated for three weeks. From this study, the positive control group which was given only lead acetate all through the duration of study had reduced levels of

testosterone, LH, FSH, inhibin B and sperm count at the fourth week of administration. This reveals that the lead acetate group had higher levels of ROS which goes a long way to interfere with the communication between leydig cells and HPG axis thereby lowering testosterone levels.

Results from this study indicate that the levels of testosterone were significantly raised in the groups treated with Mascum and Energy 3000. This could be attributed to the ability of the phytochemicals to stimulate the gonads for production and the ability to withstand the effect of free radicals and lipid peroxidation products released by lead acetate. These secondary metabolites are of great pharmaceutical significance due to their diverse pharmacological activities. Several authors have reported that components of Mascum herbal and Energy 3000 supplements contain protodioscin, alkaloids, tannins and saponins which have the potential to improve spermatogenic activity and maintain testicular integrity¹⁸⁻²⁰.

However, Libron herbal was significantly reduced compared to the positive control group. This observation may suggest that Libron herbal contains some potentially toxic substances capable of inhibiting testosterone production. Dixit *et al.*²¹ had earlier reported that cyclohexanol-1-ol inhibits the process of spermatogenesis at the levels of spermatocyte and spermatids in albino rats. Spermatocytes were seen to be reduced in the lumen of the seminiferous tubules and this could be attributed to the presence of some chemical compounds present in Libron as seen in its GC/MS study. Another study by Kenney *et al.*²² revealed a high risk of gonadal dysfunction in men exposed to cyclophosphamide. Seminiferous tubules were seen to be shrunken and sialic acid concentration dropped as such testosterone in this study, was reduced but no detrimental effect on the kidney and liver cells was reported.

The levels of follicle stimulating hormone were significantly raised in the groups treated with Libron and Mascum, but not in the group treated with Energy 3000 herbal. There were no significant improvements in the levels of luteinizing hormone in the rats treated with Libron and Mascum herbal supplements whereas inhibin B levels in all the treated groups were significantly different from the positive control group. Smith and Walker²³ observed a correlation between sertoli cells, leydig cells and germ cells which regulate FSH, LH and testosterone, respectively. The rise in inhibin B levels is an indication that inhibin B serves as a negative feedback mechanism for FSH and several studies show that Inhibin B are more predicting tool in establishing the testicular function and histological status of the testis than either of them²⁴.

The observation suggests an ameliorative potential of these supplements in restoring testosterone levels in the supplement-treated groups apart from Libron herbal. Semen analysis of the male rat at the end of the 28 days (4 weeks) treatment shows that there were significant improvements in the semen parameters in the treated groups compared to the positive control group. However, Libron herbal supplement was not able to reverse the effect of lead acetate when compared to the positive control. Some other studies have reported similar findings using herbal extracts.

Offor *et al.*²⁵ observed a significant reduction in sperm count, sperm motility and sperm viability upon treatment with lead acetate though this effect was reversed by administration of *Solanum anomalum*. Also, Sudjarwo *et al.*²⁶ administered 50 mg/kg of lead acetate for 35 days and treated with curcumin but groups given only lead acetate were seen to have reduced sperm motility.

Histological analysis of the testes in the negative group showed normal shaped seminiferous tubules with intact basement membrane containing spermatogonia, spermatocyte and spermatozoa. The surrounding basement membrane is intact whereas in the lead acetate-treated group the seminiferous tubules are vacuolated containing spermatogonia (SPG) and few spermatocytes (SPC) with distorted basement membrane (BM). Haouas *et al.*²⁷ on the reproductive toxicity of lead acetate in adult male rats reveals

similar alteration of the seminiferous tubules and depletion of germ cell components upon treatment with 2000 mg/dl of lead acetate for 35 days. For the Libron-treated group after exposure to lead acetate slightly distorted testis containing spermatogonia, reduced spermatocyte and spermatozoa (SPZ). Changes seen here could be due to free radicals released and accumulation of lipid peroxidation products produced by lead acetate and the inability of the herbal supplement to reverse this condition. But for Mascum herbal treated group a normal-shaped tubule with intact basement membrane (BM) containing spermatogonia (SPG), spermatocyte (SPC) and spermatozoa (SPZ). Similar results were seen in the Energy 3000 herbal supplement. The ability of seminiferous tubules at the therapeutic dose of Mascum herbal Pride and Energy 3000 to revert to their normal shape shows that Mascum herbal Pride and Energy 3000 does not pose any danger to the tubules instead there is a masked improvement upon administration.

CONCLUSION AND RECOMMENDATION

The findings from this study show that the herbal supplements used have the potential to ameliorate lead acetate-induced toxicity in the reproductive system of albino rats. This is probably due to the presence of phytochemical substances in these herbal formulations. However, Libron herbal could not ameliorate the toxicity impact on the levels of testosterone in the albino rats when compared to the positive control group. This observation may suggest the presence of some harmful substances in Libron that could be potentially toxic to testosterone production in albino rats. It is concluded that Mascum herbal pride and Energy 3000 used in this study possesses ameliorative potential on lead acetate-induced toxicity of the reproductive system of albino rats. It is recommended that there should be more studies to verify the efficacies and safety of various herbal supplements used for the management of health challenges that affect the reproductive hormones and not rely on the manufacturer's claims.

SIGNIFICANCE STATEMENT

Several herbal supplements are in use to curb infertility in men due to the high cost of complementary drugs and quick accessibility to herbal supplements. This study evaluated the efficacy of three herbal supplements in ameliorating lead acetate-induced infertility in adult male albino rats. Mascum herbal and Energy 3000 were found to ameliorate male infertility based on the parameters analyzed. The study there opines the ability of the aforementioned herbal supplement to ameliorate infertility in male albino rats.

ACKNOWLEDGMENT

We thank the Animal House, Department of Pharmacology, Faculty of Pharmaceutical Sciences, University of Port-Harcourt, Rivers State for their provided facilities.

REFERENCES

1. La Vignera, S., E. Vicari, R.A. Condorelli, R. D'Agata and A.E. Calogero, 2011. Male accessory gland infection and sperm parameters (review). *Int. J. Andrology*, 34: e330-e347.
2. Agarwal, A., A. Mulgund, A. Hamada and M.R. Chyatte, 2015. A unique view on male infertility around the globe. *Reprod. Biol. Endocrinol.*, Vol. 13, No. 1. 10.1186/s12958-015-0032-1.
3. Centola, G.M., 2014. Semen assessment. *Urologic Clin. North Am.*, 41: 163-167.
4. Sammons, H.M., M.I. Gubarev, L.V. Krepkova, V.V. Bortnikova and F. Corrick *et al.*, 2016. Herbal medicines: Challenges in the modern world. Part 2. European Union and Russia. *Expert Rev. Clin. Pharmacol.*, 9: 1117-1127.
5. Ekor, M., 2014. The growing use of herbal medicines: Issues relating to adverse reactions and challenges in monitoring safety. *Front. Pharmacol.*, Vol. 4. 10.3389/fphar.2013.00177.
6. Odinga, T., E.B. Essien and J.O. Akaninwor, 2018. Prophylactic potency of *Ricinodendron heudelotii* seeds against aspirin-induced ulcer. *Res. J. Life Sci. Bioinf. Pharm. Chem. Sci.*, 4: 663-669.

7. Borokini, T.I. and I.O. Lawal, 2014. Traditional medicine practices among the Yoruba people of Nigeria: A historical perspective. *J. Med. Plant*, 2: 20-33.
8. Nwogu, A.O., D.G. Tamuno-Emine, A.E. Ben-Chioma and E.A.S. Bartimaeus, 2023. Evaluation of the phytochemical composition of some commonly sold male herbal fertility supplements in Port Harcourt, Rivers State, Nigeria. *Asian J. Med. Health*, 21: 177-184.
9. Park, M., H. Cho, H. Jung, H. Lee and K.T. Hwang, 2014. Antioxidant and anti-inflammatory activities of tannin fraction of the extract from black raspberry seeds compared to grape seeds. *J. Food Biochem.*, 38: 259-270.
10. Kähkönen, M.P., A.I. Hopia, H.J. Vuorela, J.P. Rauha, K. Pihlaja, T.S. Kujala and M. Heinonen, 1999. Antioxidant activity of plant extracts containing phenolic compounds. *J. Agric. Food Chem.*, 47: 3954-3962.
11. van Andel, T. and L.G. Carvalheiro, 2013. Why urban citizens in developing countries use traditional medicines: The case of Suriname. *Evidence-Based Complementary Altern. Med.*, Vol. 2013. 10.1155/2013/687197.
12. Raynor, D.K., R. Dickinson, P. Knapp, A.F. Long and D.J. Nicolson, 2011. Buyer beware? Does the information provided with herbal products available over the counter enable safe use?. *BMC Med.*, Vol. 9. 10.1186/1741-7015-9-94.
13. WHO, 2013. WHO Traditional Medicine Strategy: 2014-2023. World Health Organization, Geneva, Switzerland, ISBN: 9789241506090, Pages: 76.
14. Ibrahim, N.M., E.A. Eweis, H.S. El-Beltagi and Y.E. Abdel-Mobdy, 2012. Effect of lead acetate toxicity on experimental male albino rat. *Asian Pac. J. Trop. Biomed.*, 2: 41-46.
15. Owumi, S.E., U.O. Arunsi, M.T. Otunla and I.O. Oluwasuji, 2023. Exposure to lead and dietary furan intake aggravates hypothalamus-pituitary-testicular axis toxicity in chronic experimental rats. *J. Biomed Res.*, 37: 100-114.
16. Paget, G.E. and J.M. Barnes, 1964. Toxicity Tests. In: *Evaluation of Drug Activities*, Laurence, D.R. and A.L. Bacharach (Eds.), Academic Press, Cambridge, Massachusetts, ISBN: 9781483228457, pp: 135-166.
17. Odinga, T.B., C.B. Lemii, I.R. Daka, C.U. Gabriel-Brisibe, S.K. Enebeli, I. Austin-Asomeji and F.U. Edward, 2023. Synergistic mixture of *Cyperus esculentus*, *Phoenix dactylifera* and *Cocos nucifera* aqueous extract: Its liver and kidney benefits in male albino rat model. *J. Biosci. Med.*, 11: 63-75.
18. Adusei, S., J.K. Otchere, P. Oteng, R.Q. Mensah and E. Tei-Mensah, 2019. Phytochemical analysis, antioxidant and metal chelating capacity of *Tetrapleura tetraptera*. *Heliyon*, Vol. 5. 10.1016/j.heliyon.2019.e02762.
19. Adelakun, S.A., B. Ogunlade, T.S. Olawuyi and A.O. Ojewale, 2021. Aqueous extract of *Tetrapleura tetraptera* fruit peels influence copulatory behavior and maintain testicular integrity in sexually mature male Sprague-Dawley rats: Pro-fertility evaluation and histomorphometry evidence. *Curr. Res. Physiol.*, 4: 7-16.
20. Ali, S., M.R. Khan, Irfanullah, M. Sajid and Z. Zahra, 2018. Phytochemical investigation and antimicrobial appraisal of *Parrotiopsis jacquemontiana* (Decne) Rehder. *BMC Complementary Altern. Med.*, Vol. 18. 10.1186/s12906-018-2114-z.
21. Dixit, V.P., R.S. Gupta, S. Kumar and B.C. Joshi, 1980. Reversible chemical sterilization: Effects of cyclohexanol administration on the testes and epididymides of male rabbit. *Indian J. Physiol. Pharmacol.*, 24: 278-286.
22. Kenney, L.B., M.R. Laufer, F.D. Grant, H. Grier and L. Diller, 2001. High risk of infertility and long term gonadal damage in males treated with high dose cyclophosphamide for sarcoma during childhood. *Cancer*, 91: 613-621.
23. Smith, L.B. and W.H. Walker, 2015. Hormone Signaling in the Testis. In: *Knobil and Neill's Physiology of Reproduction*, Plant, T.M. and A.J. Zeleznik (Eds.), Academic Press, Cambridge, Massachusetts, ISBN: 9780123971753, pp: 637-690.

24. Barbotin, A.L., C. Ballot, J. Sigala, N. Ramdane and A. Duhamel *et al.*, 2015. The serum inhibin B concentration and reference ranges in normozoospermia. *Eur. J. Endocrinol.*, 172: 669-676.
25. Offor, S.J., H.O. Mbagwu and O.E. Orisakwe, 2019. Improvement of lead acetate-induced testicular injury and sperm quality deterioration by *Solanum anomalum* Thonn. ex. Schumacher fruit extracts in albino rats. *J. Fam. Reprod. Health*, 13: 98-108.
26. Sudjarwo, S.A., G.W. Sudjarwo and Koerniasari, 2017. Protective effect of curcumin on lead acetate-induced testicular toxicity in Wistar rats. *Res. Pharm. Sci.*, 12: 381-390.
27. Haouas, Z., I. Zidi, A. Sallem, R. Bhourri, T. jina, M. Zaouali and M. Mehdi, 2015. Reproductive toxicity of lead acetate in adult male rats: Histopathological and cytotoxic studies. *J. Cytol. Histol.*, Vol. 6. 10.4172/2157-7099.1000293.